



# What is the Optimal Treatment for this Rare Entity: A Pediatric Case with the Hyalinizing Clear Cell Carcinoma of the Nasopharynx

Eda Ataseven<sup>1</sup>, Şebnem Önen Göktepe<sup>2</sup>, Göksel Turhal<sup>3</sup>, Derya Demir<sup>4</sup>, Serra Kamer<sup>5</sup>, Mehmet Kantar<sup>1</sup>

<sup>1</sup>Ege University Faculty of Medicine, Department of Pediatric Hematology and Oncology, İzmir, Türkiye

<sup>2</sup>University of Health Sciences Türkiye, Dr. Behçet Uz Pediatric Diseases and Surgery Training and Research Hospital, Clinic of Pediatric Hematology and Oncology, İzmir, Türkiye

<sup>3</sup>Ege University Faculty of Medicine, Department of Ear Nose Throat, İzmir, Türkiye

<sup>4</sup>Ege University Faculty of Medicine, Department of Pathology, İzmir, Türkiye

<sup>5</sup>Ege University Faculty of Medicine, Department of Radiation Oncology, İzmir, Türkiye

## ABSTRACT

Hyalinizing clear cell carcinoma (HCCC) is a rare low-grade malignant tumor of the minor salivary glands of the head and neck. It can also arise in the nasopharynx in rare cases. Only a few cases of nasopharyngeal HCCC (NHCCC) have been reported in the literature, and most patients are in their sixth decade of life. Due to this disease's rarity, there is no consensus on its optimal treatment. Surgical excision is the mainstay of treatment. However, the role of postoperative radiotherapy is unknown. Herein, we report on a case of NHCCC in a 14-year-old female, treated successfully with surgical resection and adjuvant radiotherapy. This patient is the youngest case of NHCCC reported in the literature.

**Keywords:** Hyalinizing clear cell carcinoma, nasopharynx, childhood, treatment, surgery

## Introduction

Hyalinizing clear cell carcinoma (HCCC) is a rare low-grade malignant tumor of the head and neck salivary glands which was first described in detail by Milchgrub et al. (1) in 1994. HCCC represents 1% of all salivary gland tumors (1,2). They arise mainly from the palate, base of the tongue, and floor of the mouth and also in the nasopharynx, maxilla, oral mucosa, or nasal cavity in rare cases (1-4).

HCCCs are low-grade malignant tumors, and they have an indolent course. Most patients are in their sixth decade of life and have a female predominance (3). They usually present with painless mass and manifest site-specific symptoms such as epistaxis, tinnitus, or nasal obstruction due to the local mass effect (2,3).

Its definitive diagnosis is based on histological examination. HCCC has a broad differential diagnosis which

## Corresponding Author

Assoc. Prof. Eda Ataseven, Ege University Faculty of Medicine, Department of Pediatric Hematology and Oncology, İzmir, Türkiye

**E-mail:** edataseven@yahoo.com **ORCID:** orcid.org/0000-0003-3419-5814

**Received:** 17.09.2024 **Accepted:** 02.12.2024 **Epub:** 18.02.2025 **Publication Date:** 17.03.2025

**Cite this article as:** Ataseven E, Önen Göktepe Ş, Turhal G, Demir D, Kamer S, Kantar M. What is the optimal treatment for this rare entity: a pediatric case with the hyalinizing clear cell carcinoma of the nasopharynx. J Pediatr Res. 2025;12(1):38-44



Copyright 2025 The Author. Published by Galenos Publishing House on behalf of Ege University Faculty of Medicine, Department of Pediatrics and Ege Children's Foundation, published by Galenos Publishing House.  
Licensed under a Creative Commons Attribution-NonCommercial-NoDerivatives 4.0 International License (CC BY-NC-ND 4.0)

includes other clear cell-containing head and neck tumors (3). Hence, it is sometimes challenging to distinguish HCCC from the other salivary gland tumors with clear cell variants based on a small biopsy sample. Antonescu et al. (5) identified a consistent Ewing sarcoma breakpoint region 1 (*EWSR1*) - *activating transcription factor-1 fusion* gene in HCCC, and this molecular signature is not present in the other clear cell tumors. Shah et al. (6) recently found that *EWSR1* rearrangements were not a feature in the other salivary gland tumors, suggesting that this *EWSR1* rearrangement is specific to HCCC and so it can be used to distinguish this lesion from other salivary gland neoplasms.

There have been only a few cases of nasopharyngeal HCCC (NHCCC) reported in the literature. Due to this disease's rarity, there is no consensus on its optimal treatment. Surgical excision is the mainstay of treatment. However, the role of adjuvant radiotherapy remains unknown. Although there is no standardized treatment regimen, positive surgical margins and particularly aggressive tumors are frequently treated with radiotherapy in order to decrease the risk of recurrence (4).

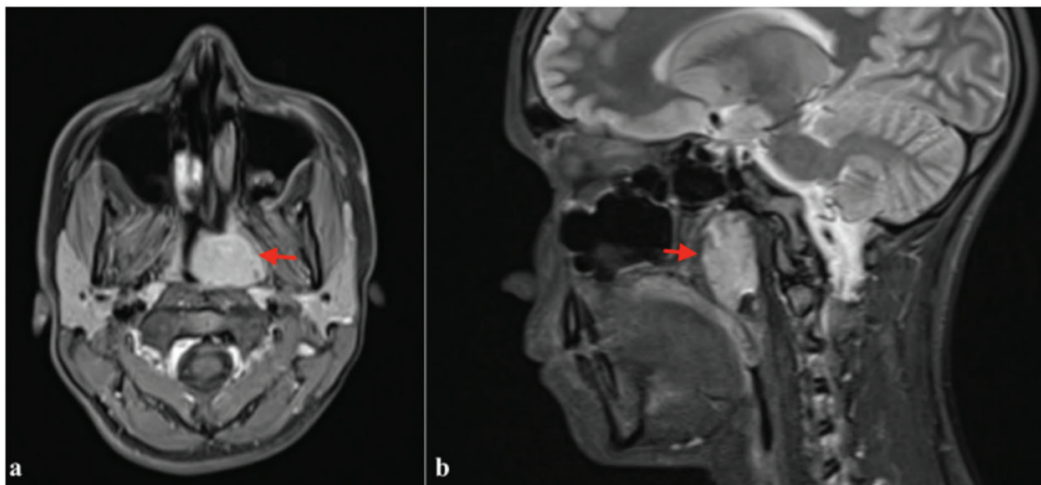
### Case Report

A fourteen-year-old female patient presented with nasal congestion and epistaxis for three months. On her physical examination, a large polypoid mass obliterated the left nasal cavity. Her head and neck examination showed no other lesions or lymphadenopathy. Magnetic resonance imaging showed a protruding nasopharyngeal mass measuring 3x2.5x2 cm in diameter, arising from the left lateral and

posterior wall, obstructing the entire nasopharynx, and extending to the Rosenmüller fossa and torus tubarius (Figure 1). A homogeneous contrast enhancement was apparent. There were also bilateral retropharyngeal and cervical lymph nodes of less than 1 cm.

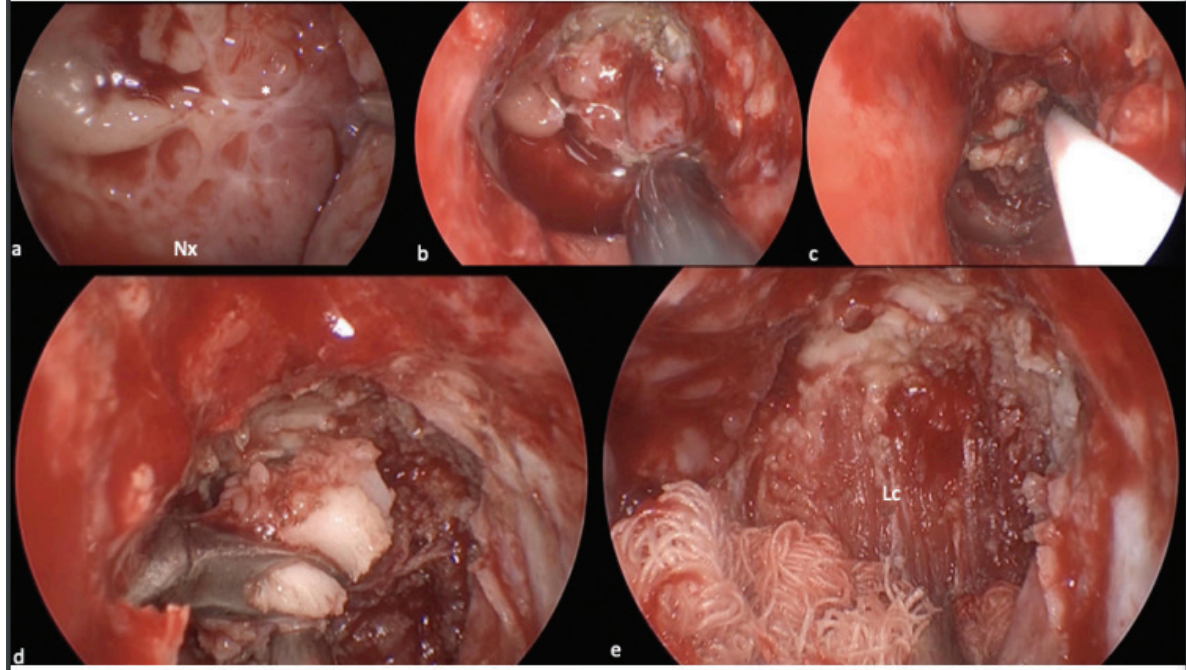
A biopsy was performed, and it showed submucosal diffuse infiltration by neoplastic epithelial cells with clear cytoplasm, round-oval nuclei, and inconspicuous nucleoli. Tumor cells were positive for periodic acid schiff with diastase soluble in histochemistry. Immunohistochemistry revealed that the neoplastic cells were positive for epithelial membrane antigen (EMA), cytokeratin (AE1/AE3), but no expression of DOG1, SOX-10, or p63. This was compatible with clear cell carcinoma. To rule out metastasis from the kidney, a positron emission tomography (PET) scan and abdominal ultrasonography (USG) were performed. The PET scan revealed an abnormal accumulation of fluorodeoxyglucose ( $SUV_{max}$ : 2.5) in the nasopharyngeal mass without any tumors in other sites of the body. Abdominal USG was normal. Tumor markers, such as alpha-fetoprotein, human chorionic gonadotropin and neuron specific enolase were within normal limits. The tumor stage was pT2N0M0. Following this, the patient underwent complete tumor resection.

The tumor originated from the left Rosenmüller fossa, and the boundaries of the resection were the base of the sphenoid sinus superiorly, the lateral nasopharyngeal wall laterally, and the midline posterior nasopharyngeal wall medially. The Torus tubarius and cartilaginous Eustachian tubes were included in the resection. The deep surgical



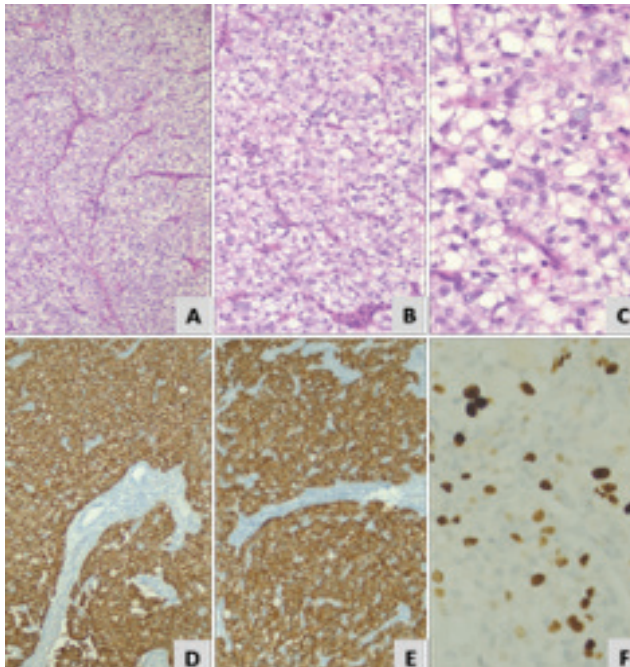
**Figure 1.** Corrected MRI scan reveals a 3x2.5x2 cm lobulated, expansile, nasopharyngeal mass which obliterates the nasopharynx and extends into the left Rosenmüller fossa

MRI: Magnetic resonance imaging



**Figure 2.** (a-c) Endoscopic views of the nasopharynx from the left nasal cavity (Nx: nasopharynx, \*: tumor) **d)** En-bloc removal of the tumor **e)** View of the nasopharynx following resection

Lc: Longus capitis muscle



**Figure 3.** Biopsy shows submucosal infiltration by neoplastic epithelial cells with clear cytoplasm (HE, x100) **(A)**, the nuclei of neoplastic cells round-oval nuclei, inconspicuous nucleoli, and some pleomorphism (HE, x200; x400) **(B, C)**, immunohistochemically, epithelial cells express cytokeratin (AE1/AE3) (IHC, x100) **(D)**, EMA (IHC, x100) **(E)**, Ki-67 (IHC, x400) **(F)**

IHC: Immunohistochemistry, EMA: Epithelial membrane antigen

margin was clear along longus capitis and longus colli muscles. An endoscopic partial nasopharyngectomy was performed using the transnasal route (Figure 2).

The resection of the tumor demonstrated the same histological features as the biopsy. Immunohistochemistry showed that neoplastic cells with clear cytoplasm expression of cytokeratin (AE1/AE3) and EMA, but no expression of p63, alpha-smooth muscle actin, S100, PAX8, TFE-3, DOG1, or SOX-10. The Ki-67 proliferation index was approximately 15% in the neoplastic epithelial cells. Chromogenic in situ hybridization (CISH) for Epstein-Barr virus-encoded small RNA was negative. Fluorescence in situ hybridization (FISH) revealed *EWSR1* gene rearrangement in the neoplastic cells. Given the morphology, immunophenotype, CISH, and FISH, the exact diagnosis was clear cell carcinoma (Figure 3). Since the patient had no evidence for the involvement of the renal tissue, besides immunohistochemically, and with TFE-3 being negative in the tumor, renal cell carcinoma was excluded.

After discussing adjuvant treatment at the tumor board, the patient underwent an intensity-modulated radiation therapy of 66 Gy targeting the nasopharynx. There was no recurrent or residual disease after 4 years of follow-up.

**Table I.** Cases of nasopharyngeal HCCC reported in the literature

Study	Age/sex	Primary tumor	Metastasis	Surgery	Radiotherapy/ dosage	Outcome
Cheng et al. (11) 2008	63/F	Right side of the nasopharynx with extension to the left choana	No	Endoscopic resection of the nasopharyngeal tumor	Performed/dosing unspecified	12 months tumor free
Dosemane et al. (12) 2015	22/F	Arising from the roof of the nasopharynx	No	Endoscopic wide excision	Performed/60 Gy	3 years tumor free
Goyal and Tanveer (13) 2009	20/M	Arising from the nasopharynx and extending into the left nasal cavity and orbit	No	Subtotal maxillectomy with left orbital exenteration and neck dissection	Performed/60 Gy	6 months tumor free
Nakashima et al. (14) 2015	27/F	Right side of the nasopharynx obstructing the eustachian tube	No	Wide resection, with 1 cm margin	No	2 years tumor free
Nakano et al. (15) 2014	27/F	Nasopharynx	No	Surgical resection	No	18 months tumor free
Fukuda et al. (16) 2015	63/F	Roof of the nasopharynx	No	Surgical excision	No	1 year tumor free
Shah et al. (6) 2013	Unspecified	Nasopharynx	Unspecified	Unspecified	Unspecified	Unspecified
Tang et al. (9) 1995	51/F	Nasopharynx	Unspecified	Transpalatal excision	Performed after second recurrence, 60 Gy	Multiple recurrences over 11 year period
Ceballos Sáenz et al. (8) 2014	38/M	Mass obliterating the lumen of the nasopharynx and extending into the left nasal cavity.	Local lymph node metastasis, no distant metastasis	Surgical excision, with residual disease	Radiotherapy and chemotherapy performed, unspecified	Not known
Malfitano et al. (4) 2019	48/M	Right side of the nasopharynx	No	Endoscopic resection of the mass and right-sided neck dissection	Performed/66 Gy	9 weeks tumor free
Wang and Fu (10) 2010	57/M	Left side of nasopharynx	No	Biopsy	Neoadjuvant chemotherapy and radiotherapy/dose unspecified	2 months tumor free
Chapman et al. (17) 2018	62/M	Nasopharynx	No	Excisional biopsy	Unspecified	5 months tumor free
Antonescu et al. (5) 2011	77/F	Nasopharynx	No	Unspecified	Performed/dosing unspecified	Unspecified
Bilodeau et al. (18) 2013 reported 3 cases	Unspecified	Nasopharynx	Unspecified	Unspecified	Unspecified	Unspecified
Hara et al. (19) 2018	18/F	Nasopharynx	No	En bloc surgical resection	No	12 months tumor free



**Table I.** Cases of nasopharyngeal HCCC reported in the literature

Study	Age/sex	Primary tumor	Metastasis	Surgery	Radiotherapy/ dosage	Outcome
Albergotti et al. (2) 2016 reported 2 cases	Unspecified	Nasopharynx	Unspecified	Unspecified	Unspecified	Unspecified
Zhao et al. (20) 2018	62/M	Nasopharynx	No	Unspecified	Unspecified	8 months tumor free
Arifi et al. (21) 2022	63/M	Nasopharynx	No	Biopsy	Chemotherapy and radiotherapy/70 Gy	12 months tumor free
Chang and Wu (22) 2024	44/M	Nasopharynx	No	Endoscopic wide excision	Chemotherapy and radiotherapy/70 Gy	12 months tumor free
Sun et al. (23) 2024 reported 2 cases	61/F 72/F	Nasopharynx	1) Local LN 2) No	Surgical excision	Chemotherapy and radiotherapy	1) 2.5 years 2) 8 months tumor free
Zhai et al. (24) 2023 reported 26 cases	30-82 years old F/M: 16/10	Nasopharynx	5 patient lymph node metastasis	Surgery: 20 patients	only RT (3 pt) S+RT (5 pt) S+ Chemo (1 pt)	5 patients died of disease
Our patient	14/F	Nasopharynx	No	Partial nasopharyngectomy	RT, 66 Gy	48 months tumor free

HCCC: Hyalinizing clear cell carcinoma, F: Female, M: Male, RT: Radiotherapy, LN: Lymph node, Gy: Gray

## Discussion

HCCCs are rare low-grade malignant tumors, and they have an indolent course. To date, 50 cases of NHCCC have been reported in the literature (Table I) (4-24). Due to the rarity of this tumor, most of these reports are clinical case reports. As of 2023, only 21 cases had been reported in the literature. However, in October 2023, Zhai et al. (24) published the largest case series to date, reporting on 26 cases from a single institution. Of these 50 cases, only 43 had detailed information on clinical presentation, treatment, and follow-up. The mean age of the reported 43 patients was 52 years (18-82 years), and twenty-six (60%) were female. To our knowledge, our patient is the youngest patient reported in the literature to date.

Most of the time, HCCCs have an excellent prognosis (4). Local or distant metastases at presentation are uncommon in HCCC. Solar et al. (7) reviewed 52 cases of HCCC independent from localization, reported local lymph node metastasis at 23%, and recommended careful evaluation of the neck and the removal of regional lymphatics. There were no cases of NHCCC presenting with distant metastases in the literature - only seven patients from 43 cases (16%)

presented with local cervical lymph node involvement (8,23,24).

There is currently no consensus on the standard treatment. The recommended treatment for HCCC is a wide surgical resection, followed by partial or modified neck dissection in the presence of cervical lymph node metastases (4,8). The effects of chemotherapy and irradiation after surgery are controversial because of the rarity of HCCC.

In the 17 single case reports, four patients were treated with complete surgical excision, and six were treated with surgery and postoperative adjuvant radiotherapy. Of these six patients, five had an excellent prognosis with no evidence of mortality. Only Tang et al. (9) reported a patient who experienced multiple recurrences; However, this case had an incomplete initial surgical excision. Of the 17 reported cases, six presented with extensive disease, and two had local lymph node metastasis (8,10,21-23). These six cases were treated with chemotherapy, surgery, and radiotherapy.

We evaluated the study by Zhai et al. (24) separately from the others because it is the largest case series in the literature, consisting of 26 cases reported retrospectively from a single center. Of the 26 patients included in their

study, the treatment details of 23 patients were available. Of these 23 patients, 14 had surgery alone, 5 had combined surgery and radiotherapy, 3 had only radiotherapy, and one was treated with chemotherapy and surgery due to advanced disease. In this cohort, tumor recurrence and death occurred in 2 of the 14 patients who underwent surgery alone. Tumor recurrence was detected in 3 of the 5 patients treated with surgery and radiotherapy, but all survived. Three patients who received only radiotherapy died due to progressive disease.

According to these results, complete surgical resection is the mainstay of treatment, and the role of radiotherapy remains uncertain. Case reports both with and without adjuvant radiotherapy are limited. The average follow-up for the single case reports was one year (9 weeks-3 years), excluding one case reported by Tang et al. (9) (with multiple recurrences over 11 years). These follow-up times are too short to assess the role of radiotherapy.

When compared with the literature, Zhai et al. (24) reported a high recurrence rate (23%) (6/26 patients). However, their study has longer follow-up periods (6-192 months) compared to the other single-case reports.

In the present case, we employed endoscopic partial nasopharyngectomy and adjuvant radiotherapy. An adequate safety margin could not be obtained due to the anatomical complexity of the nasopharynx, and the long-term risk of recurrence remains unknown. Albergotti et al. (2) reviewed patients with head and neck clear cell carcinomas treated by surgical resection without documented positive margins or evidence of metastasis at resection, reporting a 20.4% risk of recurrence. There was one case of recurrent NHCCC among the 17 single case reports in the literature, and no patients died from disease progression. However, as mentioned earlier, there are limited cases of NHCCC, and the follow-up periods in these reports are too short. When reviewing the study by Zhai et al. (24) it is evident that the risk of seeing relapse and/or mortality becomes higher with longer-term follow-ups. As a result, long-term follow-ups of these patients are necessary.

The case presented here highlights the importance of a detailed evaluation for a definitive diagnosis. In the treatment of NHCCC, wide local excision is recommended. Despite ongoing controversy regarding the role of radiation in its treatment, adjuvant radiotherapy should be recommended when total surgical removal of the primary tumor is not achieved or for clinically aggressive tumors. Since the reported cases of NHCCC are rare, more cases

are needed in order to discuss the role of postoperative radiotherapy, and long-term follow-ups of these patients are essential.

## Ethics

**Informed Consent:** The written informed consent form was taken from the patient and family to publish the case.

## Footnotes

### Authorship Contributions

Surgical and Medical Practices: E.A., Ş.Ö.G., G.T., D.D., S.K., M.K., Concept: E.A., Ş.Ö.G., Design: E.A., Data Collection or Processing: E.A., Ş.Ö.G., Analysis or Interpretation: E.A., Literature Search: E.A., Ş.Ö.G., S.K., M.K., Writing: E.A., Ş.Ö.G., G.T., D.D., S.K., M.K.

**Conflict of Interest:** No conflict of interest was declared by the authors.

**Financial Disclosure:** The authors declared that this study received no financial support.

## References

1. Milchgrub S, Gnepp DR, Vuitch F, Delgado R, Albores-Saavedra J. Hyalinizing clear cell carcinoma of salivary gland. *Am J Surg Pathol.* 1994; 18:74-82.
2. Albergotti WG, Bilodeau EA, Byrd JK, et al. Hyalinizing clear cell carcinoma of the head and neck: case series and update. *Head Neck.* 2016; 38:426-33.
3. Weinreb I. Hyalinizing clear cell carcinoma of salivary gland: a review and update. *Head Neck Pathol.* 2013; 7(Suppl 1):20-9.
4. Malfitano MJ, Norris MN, Stepp WH, et al. Nasopharyngeal hyalinizing clear cell carcinoma: a case report and review of the literature. *Allergy Rhinol (Providence).* 2019; 10:1-7.
5. Antonescu CR, Katabi N, Zhang L, et al. EWSR1-ATF1 fusion is a novel and consistent finding in hyalinizing clear-cell carcinoma of salivary gland. *Genes Chromosomes Cancer.* 2011; 50:559-70.
6. Shah AA, LeGallo RD, van Zante A, et al. EWSR1 genetic rearrangements in salivary gland tumors: a specific and very common feature of hyalinizing clear cell carcinoma. *Am J Surg Pathol.* 2013; 37:571-8.
7. Solar AA, Schmidt BL, Jordan RC. Hyalinizing clear cell carcinoma: case series and comprehensive review of the literature. *Cancer.* 2009; 115:75-83.
8. Ceballos Sáenz C, Argyris PP, Manivel JC, Urias Barreras CM, Koutlas IG. Nasopharyngeal hyalinizing clear cell carcinoma: report of the histopathologic features of a case showing EWSR1 rearrangements by FISH and literature review. *Int J Surg Pathol.* 2014; 22:667-72.
9. Tang SK, Wan SK, Chan JK. Hyalinizing clear cell carcinoma of salivary gland: report of a case with multiple recurrences over 12 years. *Am J Surg Pathol.* 1995; 19:240-1.
10. Wang F, Fu Z. Primary clear cell carcinoma of the nasopharynx: a case report. *Chin Ger J Clin Oncol.* 2010; 9:493-94.

11. Cheng LH, Lin YS, Lee JC. Primary clear cell carcinoma of the nasopharynx. *Otolaryngol Head Neck Surg.* 2008; 139:592-93.
12. Dosemane D, Lobo FD, Sreedharan SS. Primary clear cell carcinoma of the nasopharynx. *J Cancer Res Ther.* 2015; 11:928-30.
13. Goyal R, Tanveer N. Primary clear cell carcinoma of nasopharynx-a rare entity. *Indian J Sure Oncol.* 2020; 11:134-37.
14. Nakashima T, Yasumatsu R, Yamauchi M, et al. Hyalinizing clear cell carcinoma of the nasopharynx operated by trans-oral and trans-palatal approach. *J Laryngol Otol.* 2015; 129 Suppl 2:95-7.15.
15. Nakano T, Yamamoto H, Nishijima T, et al. Hyalinizing clear cell carcinoma with EWSR1-ATF1 fusion gene: report of three cases with molecular analyses. *Virchows Arch.* 2015; 466:37-43.
16. Fukuda A, Tagami Y, Takasawa A, et al. Nasopharyngeal hyalinizing clear cell carcinoma with EWSR1 rearrangements diagnosed by fluorescence in situ hybridization. *Auris Nasus Larynx.* 2015; 42:412-15.
17. Chapman E, Skalova A, Ptakova N, et al. Molecular profiling of hyalinizing clear cell carcinomas revealed a subset of tumors harboring a novel EWSR1-CREM fusion. *Am J Surg Pathol.* 2018; 42:1182-89.18.
18. Bilodeau EA, Weinreb I, Antonescu CR, et al. Clear cell odontogenic carcinomas show EWSR1 rearrangements: a novel finding and a biological link to salivary clear cell carcinomas. *Am J Surg Pathol.* 2013; 37:1001-5.
19. Hara M, Otsuki N, Yanagisawa S, et al. A case of nasopharyngeal clear cell carcinoma diagnosed by molecular analysis. *Acta Otolaryngologica Case Reports.* 2018; 3:34-8
20. Zhao YN, Wang X, Liang FH, et al. Hyalinizing clear cell carcinoma of salivary glands: A retrospective study focused on uncommon morphology, immunohistochemistry, and detection of gene fusion using fluorescence in situ hybridization. *Pathol Res Pract.* 2018; 214:380-84.
21. Arifi S, Hammas N, Ait Erraisse M. Clear cell carcinoma of minor salivary glands: the nasopharynx, an uncommon site of origin. *Cureus.* 2022; 14:e25033.
22. Chang YW, Wu HM. Hyalinizing clear cell carcinoma in the nasopharynx: a case report and literature review. *Medicine (Baltimore).* 2024; 103:e39163.
23. Sun H, Yuan J, Cheng Q, et al. Case report: Successful management of primary hyalinizing clear cell carcinoma in nasopharynx: a report of 2 cases and system analysis. *Front Oncol.* 2024; 14:1384913.
24. Zhai C, Yuan C, Sun J, et al. Clinical and histopathologic analyses of nasopharyngeal hyalinizing clear cell carcinoma: a series of 26 cases with molecular confirmation. *Am J Surg Pathol.* 2023; 47:1168-75.